

Wrinkles Around the Mouth* Needle Treatment

ALBERT P. SELTZER, M.D.,

Philadelphia, Pa.,

Department of Plastic and Reconstructive Surgery,

St. Luke's and Children's Medical Center, Philadelphia, Pennsylvania

FACIAL disfigurements appear with advancing age. Most of these skin changes do not require a complete face lift. However, there is one that is common, perplexing and even frustrating to the plastic surgeon. It is called "Granny" or "Grandma" lips, wrinkles around the mouth, usually more marked on the upper lip. These are vertical wrinkles, above and below the vermillion edges of the lips. Such wrinkles are a give-away of age, due to considerable loss of tissue elasticity (Fig. 1a). Often, they are accompanied by dental loss and denture looseness.

GALVANI'S KEY TO DISCOVERY

One evening in the latter part of the 18th century, an Italian woman was in her kitchen watching frogs' legs which she was preparing for the evening meal. "Look at those muscles moving," she said. "They always seem to come alive when I hang them on the copper wire." Her husband, Luigi Galvani (1737-1798) looked. The cut end of the frog's nerve was in contact with the copper wire, and an electric current produced by the contact was passed along the nerve to the muscle. Galvani thus discovered the key to electricity, nerve conduction and muscle action.

DERMABRADER MAY BE DANGEROUS

In preparing to use the dermabrader, which I did in 30 patients with circumoral wrinkles, they were meticulously marked with methylene blue or brilliant green applied with a fine pointed applicator (Fig. 1b). Then, the area was injected with a solution of one per

cent novocaine and 1:50,000 epinephrine (Fig. 1c). The local anesthetic bulged up the lip to make it more prominent; in addition, a folded piece of gauze was placed under the lip.

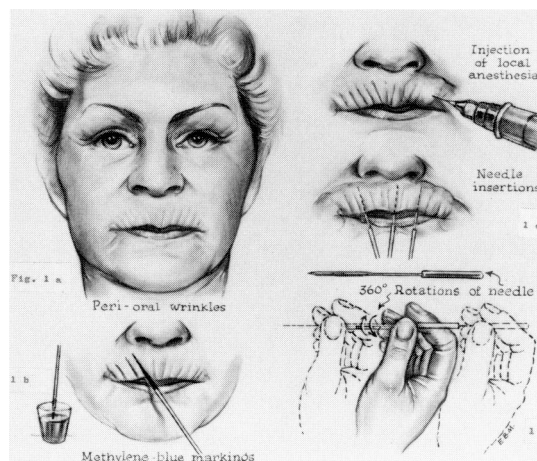


Fig. 1. See text for description.

However, the dermabrader, which rotates at the extremely high rate of 15,000 to 30,000 times a minute, is fraught with danger to the extent that loss of the lip can occur unless extreme care is exercised. In some of my cases, I used the dermabrader in combination with a face lift, but it was not successful in that repeat operations were necessary, increasing the danger to the lip.

TECHNIQUE WITH NEEDLES

My studies of acupuncture with Chinese physicians in Hong Kong, 100 hours in training with the New York Society of Acupuncture in New York City and visits to several such centers prompted me to consider the use of these needles, with or without local anesthesia, in the treatment of wrinkles around the mouth. It occurred to me that,

*Presented before the Eightieth Annual Meeting of the American Academy of Ophthalmology and Otolaryngology, Dallas, Texas, September 21-25, 1975.

with or without local anesthesia, such needles would be less dangerous than the use of the dermabrader in the treatment of circumoral wrinkles.

Each wrinkle is outlined as above (Fig. 1b) and the lip is made more prominent with the placement of folded gauze under it. Local anesthetic may be injected (Fig. 1c), but the needle procedure can be done without anesthesia. The needle insertion may be felt, but the rest is painless.

After inserting the needle under the wrinkle, each needle is rotated 360 degrees. At the same time it is moved up and down the furrow crease in the orbicularis muscle. The purpose is to irritate the muscle, and by touching the nerve filament there to produce a spasm in the muscle.

I tried stainless steel needles, each 2½ inches long, which are finer, but I prefer copper needles, each 2 and ¾ inches long and thicker, a la Galvani. The needles are left in the creases for half an hour, rotating each needle frequently while moving it up and down the complete furrow, previously marked out by the dye (Fig. 1d). To get a better grasp on each needle adhesive tape is placed around the distal half inch of these.

RESULTS OF NEEDLE TREATMENT

After treating each wrinkle with a copper needle, though sometimes a very light Galvanic current, sufficient to cause muscular contraction, can be sent through the needles, but no current is used. Then a ring of medi-

cated gauze is placed over the entire circumoral area as is done after dermabrasion of this area.

My technique is fruitful, but in some instances, it has to be repeated. Just as in every face lift, the patient is sometimes not satisfied with the result, the same is true with the needle treatment of wrinkles around the mouth. This method of treatment is not dangerous. However, in experienced hands it may be combined with dermabrasion, again emphasizing that the dangers in the use of the dermabrader must be kept in mind.

SUMMARY

A new technique for the treatment of "Granny" or "Grandma" lips, wrinkles around the mouth, is described. This facial disfigurement, due to the loss of tissue elasticity with advancing age, may be perplexing, even frustrating, to the plastic surgeon. The use of the dermabrader in the treatment of circumoral wrinkles may be fraught with danger.

Based on Galvani's key to the discovery of electricity, nerve conduction and muscle action, along with my own experience in the use of acupuncture needles, I adapted the use of copper needles to the treatment of wrinkles about the mouth. This method of needle treatment can be done with or without local anesthesia. Although the procedure may occasionally have to be repeated, the results in eradicating circumoral wrinkles are better and much less dangerous than with the dermabrader.

(Kumar et al., from page 302)

- pie Sonderb, 69:1-7, 1969.
8. MOLANDER, D. W. and G. T. PACK. Lymphosarcoma: Choice of Treatment and End-results in 567 Patients; Role of Surgical Treatment for Cure and Palliation. *Rev. Surg.*, 20:3-31, 1963.
 9. PETERS, M. V. and R. HASSELBACK, and T. C. BROWN. The Natural History of the Lymphomas Related to the Clinical Classification, in Zarafonitis C. J. (ed): *Proceedings of the International Conference on Leukemia-Lymphoma*. Philadelphia. Lea & Febiger, 1968, pp. 357-371.
 10. ROSENBERG, S. A. and H. D. DIAMOND, B. JASLOWITZ, et al. Lymphosarcoma: A Review of 1269 Cases. *Medicine*, 40:31-84, 1961.
 11. FREEMAN, C. and J. W. BERG, and S. J. CUTLER. Occurrence and Prognosis of Extranodal Lymphomas. *Cancer*, 29:252-260, 1972.
 12. STEG, R. F. et al. Malignant Lymphoma of the Mandible and Maxillary Region. *Oral Surg.*, 12:128-141, 1959.
 13. COOK, H. P. Oral Lymphomas. *Oral Surg.*, 14:690-704, 1961.
 14. ELIAS, E. G. and A. MITTELMAN. Lymphoma of Head and Neck Masquerading as Carcinoma. *Am. J. Surg.*, 122:424-426, 1971.
 15. LARSON, R. R. and G. J. HILL, II and E. R. ROTZER. Reticulum Cell Sarcoma in Head and Neck Surgery. *Am. J. Surg.*, 123:338-342, 1972.